



DATE PRESENTING CLINICAL SIGNS

History: Syncope. Started on pimobendan 10 mg BID and enalapril 10 mg BID.

5/27/22

ECHOCARDIOGRAPHIC FINDINGS

2D, M-mode, and Doppler study.

PERFORMED BY:

Dr. Meredith Swart

Left atrial size is normal. The mitral valve appears normal. Left ventricular dimensions are normal. The endocardium of the interventricular septum is hyperechoic. Left ventricular systolic function is normal. The aorta and aortic valve are normal. Right atrial and right ventricular dimensions are normal. The tricuspid valve appears normal. The pulmonary artery and pulmonary are normal. No shunting lesions are visualized. No pericardial effusion or cardiac masses are seen.

INTERPRETED BY

Keith Blass, DVM,
MS, DACVIM
(Cardiology)

LVIDd - 39.7 mm
LVIDs - 28.3 mm
FS - 28.7%
LVOT - 1.42 m/s
RVOT - 1.14 m/s

PATIENT

Brody Fur Sisters
Rescue

ASSESSMENT/RECOMMENDATIONS

SPECIES

Canine

The only potential abnormality seen in this exam is hyperechogenicity of Brody's interventricular septal endocardium. It's difficult to say what the underlying cause of the hyperechogenicity is, though it's unlikely to have any hemodynamic implications. As such, no reason for Brody's syncopal episodes is seen in this exam, and an arrhythmia and vasovagal syncope should be considered as likely differentials.

BREED

American Bulldog

Based on the results of the pending ECG, a Holter and/or event monitor may be warranted for further evaluation of Brody's syncopal episodes.

No therapy is recommended based on this exam.

SEX

A recheck echocardiogram is recommended if new physical exam and/or clinical abnormalities suggestive of the presence of structural heart disease develop.

MN

AGE

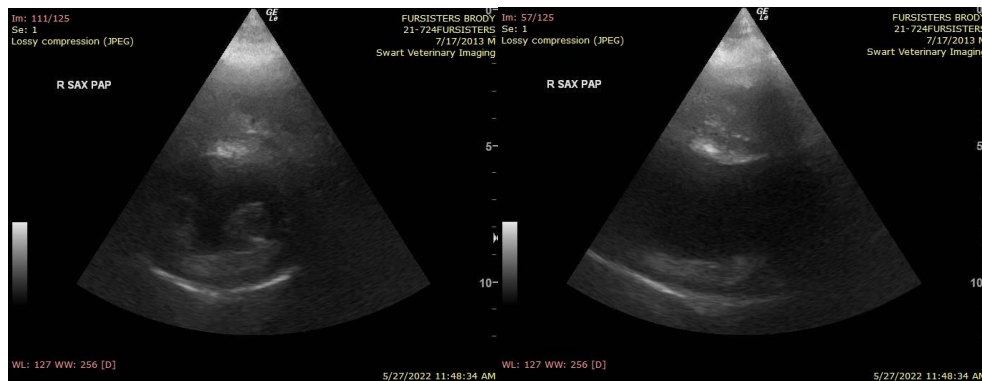8 y

WEIGHT

73 lb

HOSPITAL NAME

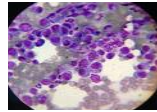
Swart Veterinary
Imaging



The information and recommendations provided are based on the images presented by the referring veterinarian. No evaluation can be communicated regarding pathology that was not visible in the image/video clips provided.

REFERRING VET

Dr. Swart



DATE Thank you for this referral. If the clinical or image interpretation does not parallel your findings or if I can be of any further assistance please contact me.

5/27/22

PERFORMED BY: Keith Blass, DVM, MS, DACVIM (Cardiology)
KeithBlass@gmail.com
631-804-5754

Dr. Meredith Swart

INTERPRETED BY

Keith Blass, DVM,
MS, DACVIM
(Cardiology)

PATIENT

Brody Fur Sisters
Rescue

SPECIES

Canine

BREED

American Bulldog

SEX

MN

AGE

8 y

WEIGHT

73 lb

HOSPITAL NAME

Swart Veterinary
Imaging

REFERRING VET

Dr. Swart